

# Aesthetic Surgery Journal

<http://aes.sagepub.com/>

---

## Shoelace Breast Cast

Daniel C. Mills II, Alexander Q. Ereso, Cora Engle and Lauren E. Cessna  
*Aesthetic Surgery Journal* 2014 34: 776 originally published online 2 May 2014  
DOI: 10.1177/1090820X14531595

The online version of this article can be found at:  
<http://aes.sagepub.com/content/34/5/776>

---

Published by:



<http://www.sagepublications.com>

On behalf of:



[American Society for Aesthetic Plastic Surgery](http://www.aesplasticsurgery.org)

**Additional services and information for *Aesthetic Surgery Journal* can be found at:**

**Email Alerts:** <http://aes.sagepub.com/cgi/alerts>

**Subscriptions:** <http://aes.sagepub.com/subscriptions>

**Reprints:** <http://www.sagepub.com/journalsReprints.nav>

**Permissions:** <http://www.sagepub.com/journalsPermissions.nav>

>> [Version of Record](#) - Jun 24, 2014

[OnlineFirst Version of Record](#) - May 2, 2014

[What is This?](#)



# Shoelace Breast Cast

Daniel C. Mills II, MD, FACS; Alexander Q. Ereso, MD;  
Cora Engle, RN; and Lauren E. Cessna, BA

Aesthetic Surgery Journal  
2014, Vol. 34(5) 776–781  
© 2014 The American Society for  
Aesthetic Plastic Surgery, Inc.  
Reprints and permission:  
[http://www.sagepub.com/  
journalsPermissions.nav](http://www.sagepub.com/journalsPermissions.nav)  
DOI:10.1177/1090820X14531595  
[www.aestheticsurgeryjournal.com](http://www.aestheticsurgeryjournal.com)

## Abstract

Implant malposition after breast augmentation surgery remains a common complication. Several surgical options exist to correct the resultant deformity; however, all involve additional risks, costs, and the increased potential for patient dissatisfaction. In my practice, I have developed a nonsurgical therapy using shoelaces, which, when tied and placed in a certain fashion, can correct this deformity. When worn continuously, the shoelaces act as an external breast cast that allows the inframammary fold to be set and heal in the correct position. I have achieved great success in using this nonsurgical technique, and it allows me to be aggressive in cases where I need to raise the inframammary fold because I know that I can easily correct if the fold is lowered too much.

## Keywords

augmentation mammoplasty, implant malposition, breast asymmetry, breast cast, shoelace therapy, double-bubble deformity

Accepted for publication December 18, 2013.

## BACKGROUND

Augmentation mammoplasty is one of the most commonly performed procedures by plastic surgeons. According to the American Society for Aesthetic Plastic Surgery, more than 330 000 breast augmentations were performed in 2012, making augmentation mammoplasty the most common cosmetic surgery procedure in the United States.<sup>1</sup> Despite the development of myriad approaches, as well as refinements to surgical techniques, complications still exist—including the need for revisional surgery. Cunningham and McCue examined the reoperation rate for primary augmentation using the Mentor (Santa Barbara, California) MemoryGel Core clinical study and determined it to be 19.4% at 6 years.<sup>2</sup> Of the patients who required reoperation, capsular contracture (CC) was the most frequently reported reason (33.3%); asymmetry was the reason in less than 5%. In some cases, asymmetry may result from malposition of the implant along the inframammary fold. In another series, involving 92 consecutive patients who underwent transaxillary augmentation, 8.6% of patients were found to have malposition of their implant.<sup>3</sup> In my own recently published 20-year experience, implant malposition also was the most common reason for revision.<sup>4</sup> Behind capsular contracture, implant maldisplacement remains the second most common reported complication following an augmentation mammoplasty.<sup>5</sup> Common reasons for early implant malposition include unrecognized preexisting congenital deformities, technical errors during pocket dissection, and placement of an inappropriately large implant in a breast

that had little preexisting soft tissue coverage. The inframammary fold is a key landmark when performing breast implant surgery. Its position defines the overall shape of the lower pole of the breast and influences the shape of the upper pole. Perhaps second only to asymmetry of the nipple-areola complex, inframammary fold asymmetries (even subtle ones) are instantly recognizable by patients. For an optimal cosmetic outcome, it is paramount to maintain symmetry at the time of implant placement.

Several surgical options have been developed to correct asymmetry, including changing of the pocket, capsulorrhaphy, biologic mesh agents, and explantation with delayed reimplantation.<sup>6-8</sup> Despite each technique being debated in the literature for its merits, all involve a second operation to achieve correction, as well as additional financial costs

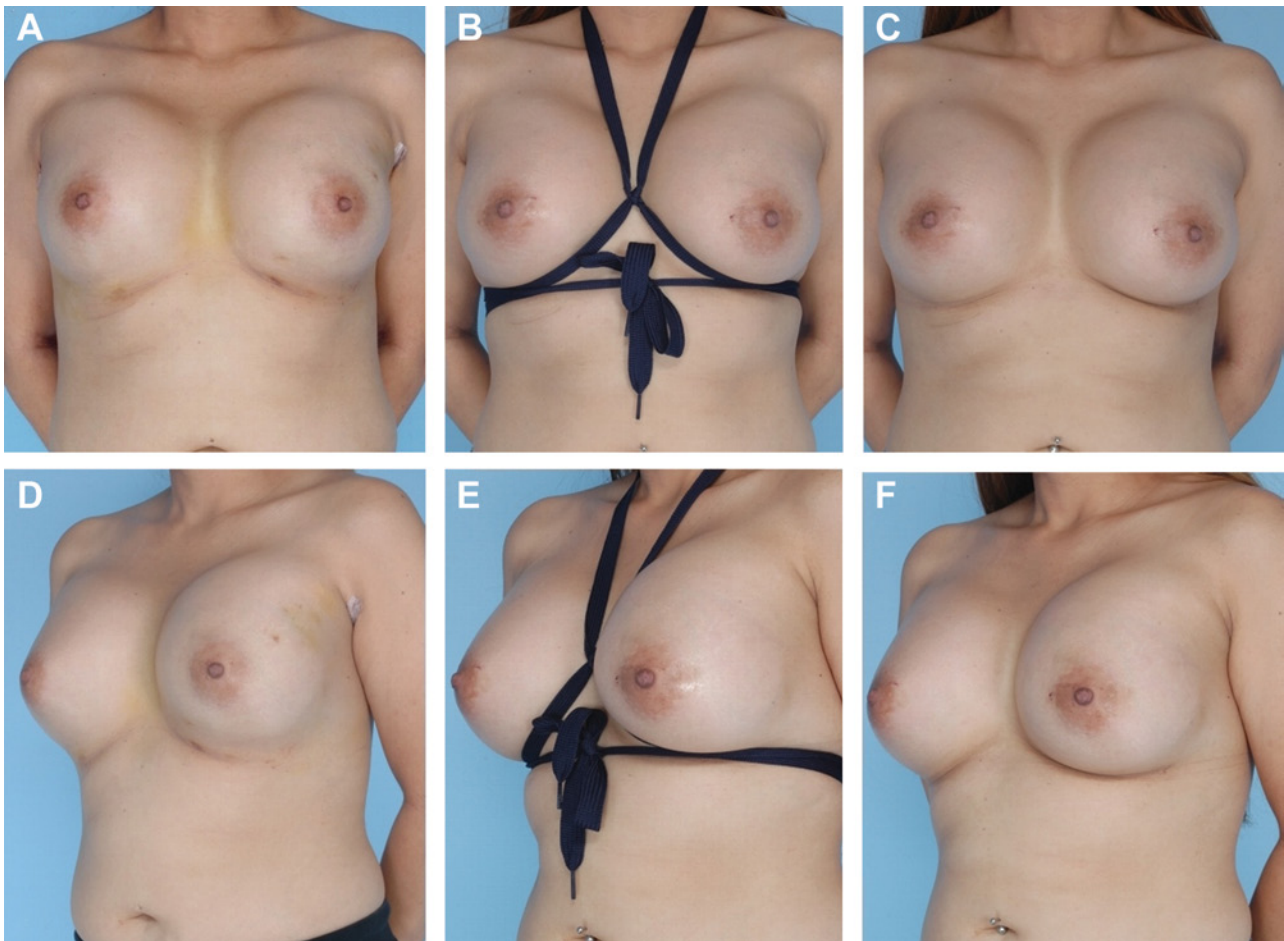
Dr Mills is a plastic surgeon in private practice; Dr Ereso is an aesthetic plastic surgery fellow at a private practice; Ms Engle is a research nurse at a private practice; and Ms Cessna is a researcher at a private practice—all in Laguna Beach, California.

## Corresponding Author:

Dr Daniel C. Mills II, Aesthetic Plastic Surgical Institute, 31852 Pacific Coast Highway, Suite 401, Laguna Beach, CA 92651 USA.  
E-mail: [dcm2@danmillssmd.com](mailto:dcm2@danmillssmd.com)



Scan this code with your smartphone to see the operative video. Need help? Visit [www.aestheticsurgeryjournal.com](http://www.aestheticsurgeryjournal.com).



**Figure 1.** (A, D) This 29-year-old patient presented 4 days after transaxillary breast augmentation. Malposition was identified, as well as a slight double-bubble deformity on both breasts. (B, E) The patient was placed in a shoelace breast cast. (C, F) Nonsurgical correction of double-bubble deformity occurred after the shoelace cast was worn for 19 days.

to the patient. Revisional surgery itself can be very challenging and usually results in a higher risk of further complications. The challenges and risks may relate to effects of the initial surgery, which include tissue atrophy, a decrease in parenchymal blood supply, and scar formation in the skin and capsule. The burden of more surgery, the potential for extra costs to patients, and greater risks for disappointing results are factors that contribute to decreased patient satisfaction.

In my practice, I developed a shoelace “breast cast” technique that achieves correction of the asymmetry without the need for revisional surgery. The purposes of placing shoelaces underneath the inframammary fold are to allow scarring of the capsule in that location to permit setting a new crease, to correct the asymmetry, and to reduce the appearance of a double bubble (Figure 1A, D). I began utilizing this technique 19 years ago when I noticed that women who wore an underwire bra early in the postoperative period could heighten the position of the lower capsule, without the risk of significant CC. I also observed, a year or 2 later, a raising of

the inframammary crease in women who had worn an underwire bra continuously. Women often did this to achieve more fullness on top; however, in doing so, some would invariably end up raising the lower margin of the capsule, necessitating surgical revision to open up the lower portion of the capsule and obtain a more inferior position of the implant. This is dependent on the amount of scar tissue that develops, which is different for each individual.

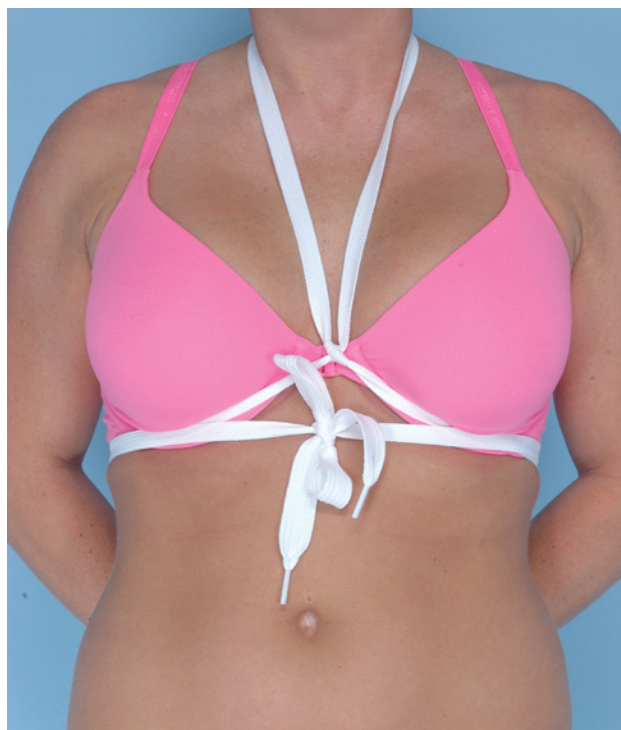## TECHNICAL DETAILS

My preferred method of performing augmentation mammoplasty is via transaxillary incision, with the implant placed under the muscle. If the patient would like to exchange an intact implant, I also prefer going through my previous transaxillary incision, unless the patient had a previous incision performed by another surgeon through a different location. For ruptured implants, especially those with significant CC, I prefer performing a capsulectomy from an anterior approach. In my practice, all patients return for a postoperative visit the

following day. For patients who receive smooth-walled implants, displacement exercises are started immediately to prevent CC. Recognizing asymmetry in the early postoperative period can be challenging, especially because the amount of swelling can differ between the breasts. Conversely, previously unrecognized anatomic conditions, when exacerbated by the augmentation, may lead to more noticeable asymmetry. Formerly, I waited at least 6 months, to allow for healing, before performing any revisional surgery to correct asymmetry. Now I can start *nonsurgical* correction immediately. I recognize that the stretch of the inframammary crease that occurs after placement of an implant is highly variable. Although certain patients may have an increased likelihood of developing an asymmetry after augmentation, I have seen patients who, upon examination, appeared to have a constricted lower pole, but when the implant was placed, the lower portion of the breast stretched well. Conversely, some patients in which good lower pole stretch was expected had a resultant double bubble. With the shoelaces, I can reliably correct the double bubble *and* avoid revisional surgery.

I have found that the ideal shoelace cast is made from two 54-inch, wide-bodied (3/4-inch), flat shoelaces. One pair of shoelaces is adequate for the duration of treatment. Rounded shoelaces tend to roll and irritate the skin. The wider shoelace seems to resist abrading the skin, and patients have expressed less discomfort with them, which in turn has increased compliance with the therapy.

The ends of the shoelaces are first tied. Then, the shoelaces are placed around the patient's neck, draped down the center of the chest, and knotted again at a location 2 to 5 cm above the inframammary crease. The shoelaces are then wrapped underneath each fold. Each end is then wrapped around the back, crossed, and brought back anteriorly, being wrapped again underneath the inframammary fold before being tied together in front. Thus, each inframammary fold is "casted" with 2 lengths of shoelaces (Figure 1B, E). (A video that demonstrates tying and placement of the shoelaces may be viewed at [www.aestheticsurgeryjournal.com](http://www.aestheticsurgeryjournal.com) or [www.surgery.org/videos](http://www.surgery.org/videos).) Tight wrapping of the shoelace is essential to prevent the implant from sneaking underneath the wrap, which could lead to a double bubble. The shoelace under the fold on the side needing to be raised is placed slightly higher than the level of where I want the crease to be set. There are 2 reasons for this. First, by "overshooting" the placement, I am accounting for the slight stretch on the scar that will occur over time due to gravity. Second, the scar will form along the caudal edge first, yielding greater strength in this area. Thus, the internal scar crease tends to be lower once the therapy has concluded (Figure 1C, F). Sometimes when we need to shorten the dome in the inferior half of the breast to decrease lower-pole projection, I will use an underwire bra to set the new inframammary crease, accompanied by



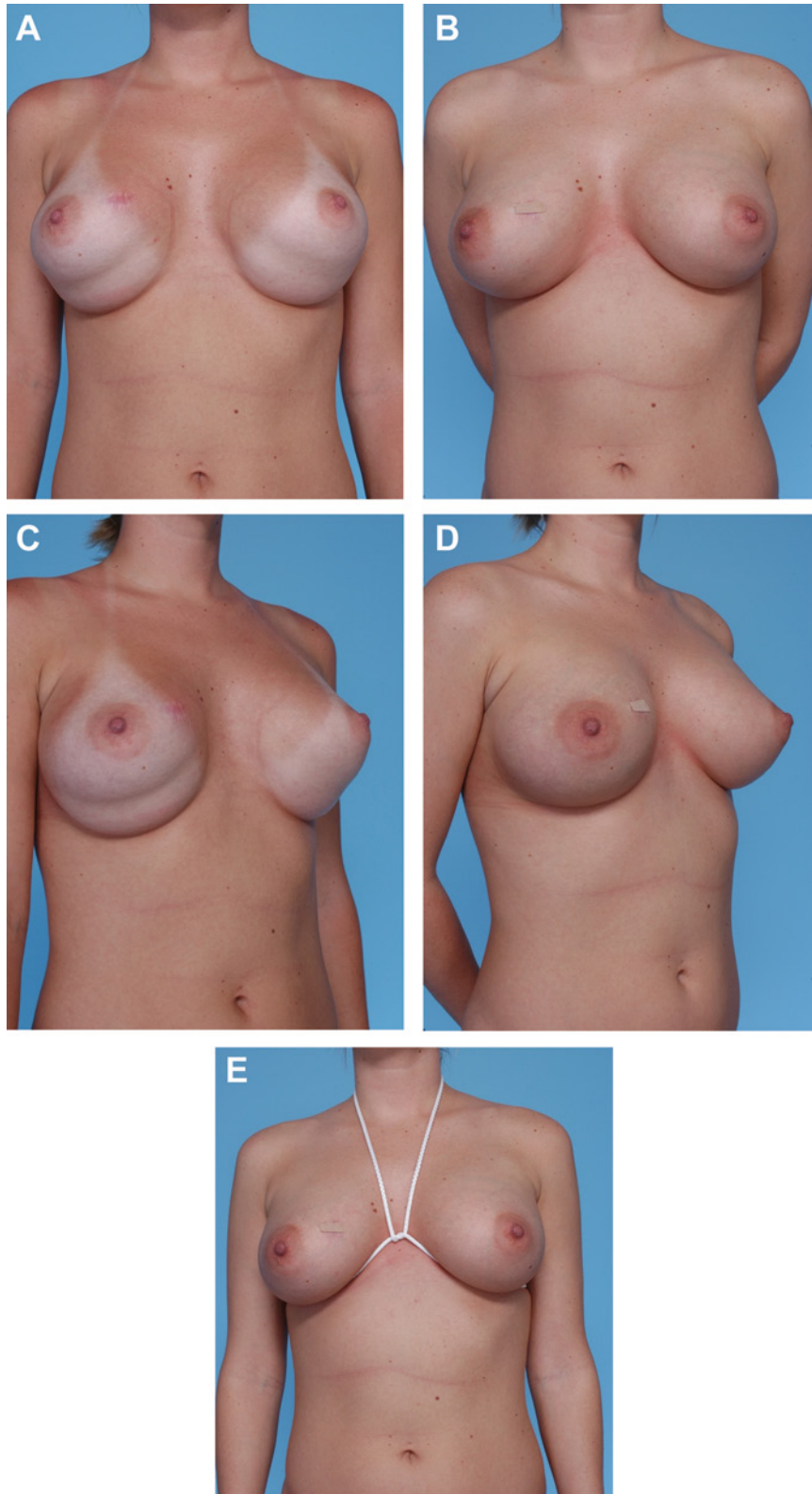
**Figure 2.** This model shows an example of a shoelace breast cast placed over the underwire bra, which acts to shorten the dome in the inferior half of the breast. The shoelaces provide additional support so that the weight of the breast does not displace the underwire bra's position along the inframammary fold. Overall, this helps to decrease projection of the lower pole of the breast.

a shoelace to provide additional support so that the weight of the breast does not displace the underwire bra's position along the crease. This can help decrease the projection of the lower pole of the breast (Figure 2). Additional clinical photographs appear in Figure 3.

## MY EXPERIENCE

I have used the shoelace breast cast in more than 200 patients. I have found that the optimal time for shoelace placement is within the first few days after surgery. I prefer waiting several days to allow any blood or irrigant to first be reabsorbed, or generalized inflammation to be resolved, so that the position of the implant can be identified clearly. However, as soon as malposition of an implant is identified, ideally within the first week, therapy should be initiated. I have found that the sooner the inframammary crease can be supported, the faster the crease can be set. Starting this therapy 4 to 6 weeks after augmentation is usually too late because the attenuated inflammatory response is not sufficient to produce the scar necessary to provide support for the implant. Consistent with normal physiologic wound healing,





**Figure 3.** (A, C) This 22-year old patient presented 10 days after transaxillary breast augmentation with a pronounced double-bubble deformity underneath both breasts. (B, D) After wearing the shoelace breast cast for 20 days, the patient's breasts demonstrated complete correction of the double-bubble deformity, which proved lasting. (E) The patient was placed in an earlier version of our shoelace breast cast.

the resultant inflammation and formation of a capsule is a well-defined physiologic response by the body to a foreign material such as the silicone implant.<sup>9</sup> The tissue formed is composed of multiple layers of collagen fibers, with a vascular layer that forms close to the implant surface. Once the pocket is created during the initial surgery, capsular surfaces left in apposition to each other will scar together as wound healing occurs.

If the shoelace cast is applied during the first week, the expected wear period to achieve adequate scar formation is approximately 2 to 4 weeks. I explain to each patient that, following initiation of therapy, she must remove the shoelaces each day (eg, when taking a shower) and check the symmetry of both inframammary folds. The day that the patient notes the position of the inframammary fold to be ideal, she should continue wearing the shoelaces for an additional period, equal to the length of time from initiation of therapy to the day that she first noted the ideal position. For example, if on the 10th day after surgery, the patient determines that her breast position is ideal, then she should continue wearing the shoelaces for an additional 10 days (for a total of 20 days). This additional wear time allows further healing, as well as scar maturation and strengthening. I do not allow patients to start taking supplemental vitamin E before therapy is complete, because I believe that vitamin E may act to inhibit the healing of the internal inframammary scar.

I prefer shoelaces to a wire bra, in most cases, for several reasons. First, I have found that the greater pressure exerted by the shoelaces (vs the wire bra) along the inframammary crease is more continuous and consistent overall. Although patients may not be especially comfortable in the shoelace cast, shoelaces are much more comfortable than a wire bra tightened to produce similar pressure. Furthermore, and particularly with higher-profile implants, I have found that implants may cause the cup of the wire bra to pull away from the anterior chest, loosening the position of the wire, resulting in the bra not being tight enough to set the scar crease. Occasionally, patients complain that the shoelace does not stay in place or tends to roll down. As stated previously, in such cases I have placed an underwire bra on the patient, followed by the shoelaces (over the wire), to prevent displacement of the shoelaces.

Throughout the patient's follow-up appointments, I obtain photographs to document progress; time points include the initiation of treatment and the 1-month follow-up. TouchMD (Cedar City, Utah) is used in my practice. It allows patients to view their own preoperative and postoperative photographs at home. Having the patients' photographs on TouchMD allows patients to track the progress of their therapy, which may yield greater compliance. I have found that the success of this therapy requires that the patient wear the shoelaces at all times until completion of therapy. When therapy is

initiated, I show the patient how to tie the shoelaces, I explain which side needs correction, and I demonstrate the ideal placement of each shoelace for both sides. I perform this while the patient is observing herself in the mirror. At this time, I also stress the importance of continuously wearing the shoelaces. Once demonstrated, I remove the shoelaces and have the patient tie the shoelaces again while I observe. Because the patient will retie the laces after bathing, it is important that she demonstrate to me before she leaves the office that she can do it correctly. I also instruct the patients to purchase several shoelaces in case of breakage or soilage.

## OUTCOMES

Lack of compliance with wearing the shoelaces as instructed is a problem occasionally, and this is the primary reason for treatment failure. However, I would estimate that the success rate for this procedure exceeds 90%. Regardless, I explain to my patients that the breast cast functions similarly to a cast for a broken bone. If she removed the cast to go dancing on a Saturday night, the bone would not heal very well. Patients usually understand and agree with this analogy. By securing the position of the inframammary crease in one position continuously, healing and scar formation will be strongest. In contrast, if the cast is not worn continuously, or is placed in different positions, poor scar formation will result, along with an inframammary crease in the wrong location.

## COST

The shoelaces can be found locally at many shoe stores, or online, for less than \$6. I believe in following the progression of therapy closely, and I do not charge patients for any postoperative follow-up visits. Because of the high success rate of this nonsurgical therapy, I believe that the shoelace breast cast is one of the most cost-effective tools in my practice.

## CONCLUSIONS

The ability to lower the inframammary crease without surgery has changed my practice in that I am more aggressive in cases of breast ptosis, where I may need to raise the inframammary crease, because I know that I can correct for this afterward—nonsurgically. Despite having this powerful nonsurgical tool at my disposal, it is paramount that the causes of implant malposition be recognized and corrected during the initial operation.

## Disclosures

The authors declared no potential conflicts of interest with respect to the research, authorship, and publication of this article.

## Funding

The authors received no financial support for the research, authorship, and publication of this article.

## REFERENCES

1. American Society for Aesthetic Plastic Surgery. Cosmetic surgery national data bank: Statistics 2012. *Aesthet Surg J.* 2013;33(2):1S-21S.
2. Cunningham B, McCue J. Safety and effectiveness of Mentor's MemoryGel Implants at 6 years. *Aesthetic Plast Surg.* 2009;33:440-444.
3. Howard PS. The role of endoscopy and implant texture in transaxillary submuscular breast augmentation. *Ann Plast Surg.* 1999;42:245-248.
4. Huang GJ, Wichmann JL, Mills DC. Transaxillary subpectoral augmentation mammoplasty: a single surgeon's 20-year experience. *Aesthet Surg J.* 2011;31:781-801.
5. Stevens WG, Harrington J, Alizadeh K, Berger L, Broadway D, Hester TR, Kress D, d'Incelli R, Kuhne J, Beckstrand M. Five-year follow-up data from the U.S. clinical trial for Sientra's US Food and Drug Administration-approved Silimed® brand round and shaped implants with high-strength silicone gel. *Plast Reconstr Surg.* 2012;130(5):973-981.
6. Cunningham B. The mentor core study on silicone MemoryGel breast implants. *Plast Reconstr Surg.* 2007;120:19S-29S.
7. Bengtson BP, Van Natta BW, Murphy DK, Slicton A, Maxwell GP. Style 410 highly cohesive silicone breast implant core study results at 3 years. *Plast Reconstr Surg.* 2007;120:40S-48S.
8. Araco A, Gravante G, Araco F, Delogu D, Cervelli V, Walgenbach K. A retrospective analysis of 3000 primary aesthetic breast augmentations: postoperative complications and associated factors. *Aesth Plast Surg.* 2007;31:532-539.
9. Speirs AC, Blocksma R. New implantable silicone rubbers: experimental evaluation of tissue response. *Plast Reconstr Surg.* 1963;31:166-175.